

Rational Surgical Tactics in Proximal Bile Ducts Tumors

Nazirov Feruz Gafurovich, Akbarov Mirshavkat Mirolimovich, Omonov Oybek Avazkhanovich 

Department of Hepatic and Biliary Ducts Surgery, Republican Specialized Center of Surgery named after Academician V. Vakhidov, Tashkent, Republic of Uzbekistan

✉ Corresponding author's Email: ooa1977@yandex.ru

ABSTRACT

This study aimed to evaluate the experience of surgical management of 156 patients with tumors of proximal parts of bile ducts. Palliative surgical interventions were performed in 125 patients. Recanalization of the tumor with external drainage of bile ducts was performed in the 61 cases. Palliative resection of biliary ducts and biliodigestive anastomosis formation was performed in 17 patients. Transcutaneous transhepatic cholangiostomy (TTCS) as a final method of treatment was performed in 33 case, and in the 14 cases we have carried out endoprosthesis placement in the stricture caused by tumor through TTCS. The radical and conditional-radical surgical interventions were performed in the 31 patients. The 19 patients have undergone the cholecystectomy, resection of hepaticocholedoch with the tumor and placement of hepatojejunoanastomosis, and in 12 cases were performed resection of hepaticocholedoch with liver resection, placement of hepaticojejunostomosis. Postoperative mortality constituted 10.2%. We studied long-term results of surgical treatment of TPBD. The recurrences of disease were noted at follow-up period from 5 months to 5 years. After operation having relatively-radical character, recurrence occurred in the period from 5 months to 12 months after radical operations – from one year to 5 years. Survival was calculated with method of multiplicand evaluations of Kaplan-Meier. Survival after radical surgeries was achieved 1 years in 94% of patients, 2 years – 82%, 3 years – 45%, 4 years – 15% and 5 years – 12%. At I and II types of tumor by Bismuth-Corlette at the II stages of the cancer of proximal bile ducts it would be rationally to perform radical surgical treatment with preliminary decompression of the intrahepatic bile ducts.

Original Article

PII: S225199391700012-7

Rec. 08 Sep. 2017

Acc. 21 Oct. 2017

Pub. 25 Nov. 2017

Keywords

Klatskin tumor,
Mechanical jaundice,
Transcutaneous
transhepatic
endobiliary
intervention,
Radical surgical
interventions

INTRODUCTION

The tumors of proximal bile ducts (TPBD) accounted for 10-26% of all malignant lesions of the bile ducts. The frequency rate varied from 2 to 8 per 100000 of population [1-3]. The clinical manifestations of the tumors with localizations in the portal fissure were described in the literature for the first time in 1957. In 1965 Klatskin G. published a lot of observations in patients with cancer of the common hepatic duct [4, 5, 7].

At present time the majority of specialists classified the tumor of Klatskin as independent disease related to the tumors originated from epithelium of the biliary ducts in the interval between the place of confluence into the common hepatic duct of the gallbladder and segmental hepatic ducts of the secondary order [9]. There are met

other names, such as portal cholangiocarcinoma, hilus tumor, portal fissure cancer. The survival duration depends directly on the efficacy of the surgical treatment [5].

The tumors of proximal bile ducts are slowly growing neoplasms having distant metastases at the early stages of disease. Local invasion of the tumor in the liver parenchyma or elements of its hilus as well as perineural invasion are found at the early stages of the tumor development, that be conditioned by the difficulties of the radical operative intervention [2, 5, 6].

The diagnosis of tumor is based on the study of the level of tumor markers (CA-19-9), findings of the ultrasound investigation (USI), direct methods of the biliary ducts contrast (retrograde cholangiopancreatography – RPCG, transcutaneous transhepatic cholangiography – TTCG), and computed tomography (CT). In rare cases the angiographic investigation and thin needle biopsy have to be performed [8].

This study aimed to improvement of the results of complex treatment of the patients with tumors of the proximal biliary ducts with choice of rational surgical technique.

MATERIAL AND METHODS

The Republican Specialized Center of Surgery named after Academician V.Vakhidov have experience of the complex treatment of 156 patients with tumors of extrahepatic biliary ducts of proximal localization during the period from 1997 to 2016. The patients were at the age of 18 to 87 years.

For classification of the tumors of proximal biliary ducts we used classification by system TNM for cancer of the extrahepatic biliary ducts and classification proposed by Bismuth-Corlette (1975) for tumor prevalence [9].

Classification for distribution of Bismuth-Corlette (1975):

Type I – tumor of the common hepatic duct without infiltration of its bifurcation;

Type II – tumorous obstruction of confluence of the lobular ducts;

Type III_a – predominant invasion of confluence and right hepatic duct;

Type III_b – predominant invasion of confluence and left hepatic duct;

Type IV – tumorous lesion of the both hepatic ducts.

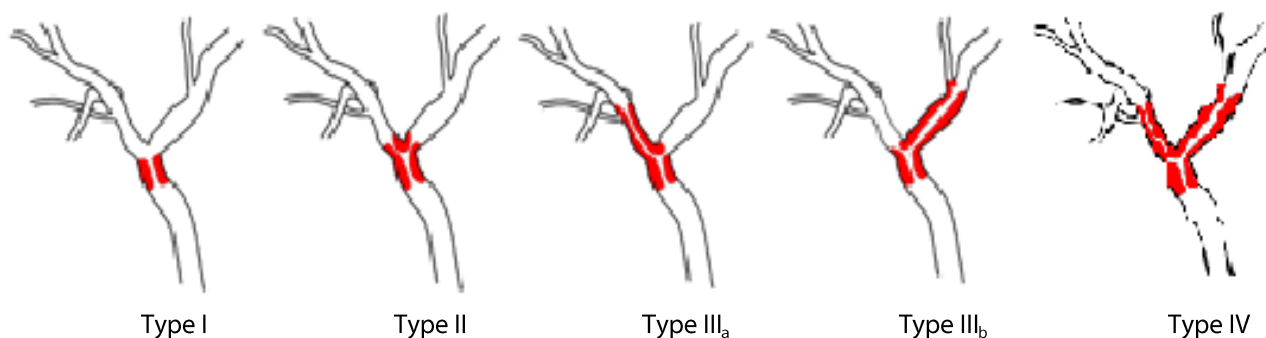


Figure1. Distribution of TPBD by classification of Bismuth-Corlette

According to this classification tumor of type I was found in 18 patients (11.5%), type II – in 26(16.6%), type III_a – in 17(10.8%), type III_b – in 31(19.8%) and type IV was diagnosed in 64 patients (41.0%).

The leading expression of disease is painless obstructive jaundice which was observed in 100% of patients. The level of bilirubinemia fluctuated from 35.6 to 770 $\mu\text{mol/l}$. The most part of these patients (56.4%) had jaundice of severe degree (higher than 300 $\mu\text{mol/l}$). In the clinical symptomatics there was also noted pruritus (77%), signs of cholangitis (56.4%) and weight loss (20%).

Diagnosis of proximal tumors of extrahepatic biliary ducts included special instrumental methods of investigation. Instrumental methods: ultrasound investigation was performed in all patients, computed tomography – 44, endoscopic retrograde cholangiography – 97, transcutaneous transhepatic cholangiography – 72 and double direct contrast of the biliary ducts – 16 patients. Ultrasound dopplerography of the hepatic vessels was used in 19 patients. Additionally there was performed radioisotope hepatoscintigraphy in 9 patients.

Ethical approval

The review board and ethics committee of Republican Specialized Center of Surgery named after Academician V. Vakhidov approved the study protocol and informed consent were taken from all the participants.

RESULTS AND DISCUSSION

Analysis of the results showed, that determination of the level of block of bile deviation is one of the key moment in the determination of the further tactics of treatment. The ultrasound investigation is the main oriented noninvasive method (USI). Echographic features of TPBD are presented by dilatation of the intrahepatic ducts, absence of visualization under stricture of the sites of the system of ducts, and presence of the collapsed gallbladder. It is important, that the Klatskin tumor is difficult for identification and its borders are frequently determined according to the secondary signs to which the changes of biliary ducts above the tumorous obstruction are attributed.

The computed tomography (CT) was used for identification of nonspecific signs, such as atrophy of one from liver lobes and hypertrophy of the contralateral that may indirectly indicate about tumor invasion into the branches of the portal vein. The sensitivity of CT achieved 88% of cases, tumorous cause of the obstruction was determined in visualization of the tumorous masses, as a rule, in intravenous bolus contrast and accounted for 55% of cases, the evaluation of respectability appeared to be correct in 42% of cases. Computed tomography gave more information while performing it before drainage of the hepatic ducts, because decompression of the biliary ducts before CT-investigation reduced sensitivity of the method at measurement of the level of the block of biliary ducts. During performance of CT before drainage of biliary ducts the proximal level of obturation was determined in 98.1% of investigation.

Today the nucleic magnetic resonance in the regime of cholangiography appeared to be the most optimal and effective method of diagnosis in TPBD, because it allows to determine clear localization and distribution of the tumor, as well as to visualize in details structure of the hepatic vessels and their link with tumor and biliary ducts. Sensitivity of MRI achieved 93.2% [10].

After the complex of noninvasive diagnostic investigation in jaundice of moderate and severe degree the first step was decompression of the biliary tree for what there were used the modern mini-invasive technologies. The preference was given to TTCCG which allows the mostly adequate drainage of the biliary tree and receiving of cholangiogram of high informativity. Sensitivity of TTCCG achieved 95.2%, accuracy of the respectability evaluation – 93%. TTCCG remains to be the “golden standard” for determination of the character of bile duct lesions in TPBD. Undoubtful advantage of TTCCG is direct link with performance of transcutaneous transhepatic cholangiostomy (TTCS), which is only real way of preventive decompression of biliary tract in the patients with proximal tumorous block before possible radical surgery (Figure 2).

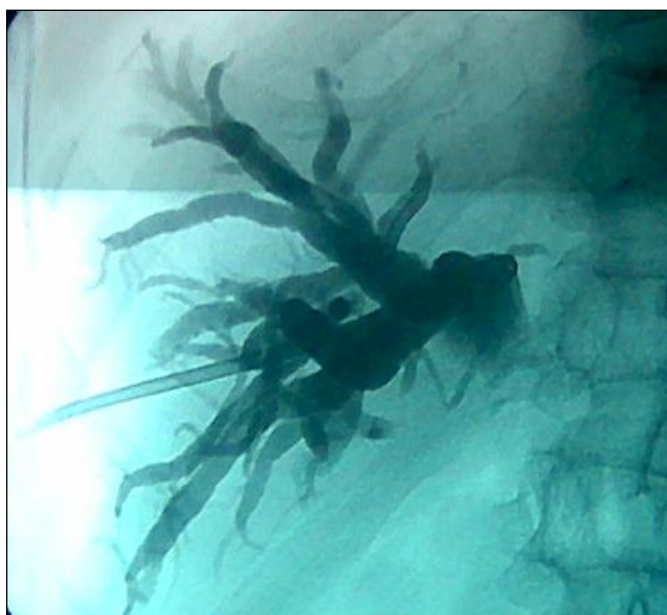

Figure 2. TTCCG and TTCS in the patients with TPBD

Endoscopic retrograde pancreatocholangiography (ERPCG) is an alternative of TTCCG, however the performance of ERPCG at the proximal blocks appeared to be problematic at absence of patency in zone of tumorous obstruction, and for evaluation of the state of biliary ducts above the place of obstruction this method is not informative [8,11]. At the associated use of ERPCG and TTCCG it may be determined length and accurate localization of the process.

In order to avoid development of the acute suppurative cholangitis and with purpose to regulate cholestasis the direct contrast methods of investigation were ended by external or external-internal drainage of the biliary ducts.

In bilirubinemia more than 200 μ mol/l the preoperative decompression of biliary ducts have to be done which may be both uni- and bilateral. The plan operative interventions were carried out 2-3 weeks after moment of decompression. In cases of TPBD non-resectability or in presence of contraindications the preference was given to mini-invasive methods of decompression of the intrahepatic biliary ducts.

Palliative operative interventions were performed in 125 (80,1%) patients with TPBD and in these cases tumor recanalization with external drainage of biliary ducts on the transhepatic drains was made in 61 cases, palliative resection of biliary ducts and biliodigestive anastomosis formation was performed in 17 patients. TTCS (external or externo-internal) – in 33 cases, endoprosthesis of the tumorous stricture through TTCS – in 14 cases. Thirteen patients underwent endoprosthesis of extrahepatic biliary ducts through TTCS (Figure 3).

The character of performed palliative operative interventions was presented in table 1. Radical and relatively-radical surgical interventions in TPBD were performed in 31 (20.3%) patients. Of them in 19(61.2%) patients was type I, in 8(25.8%) – II type and in 4 (12.9%) patients type III of tumor was revealed.

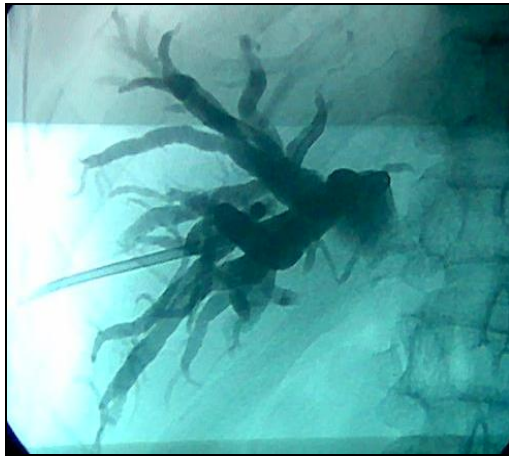


Figure 3. Endoprosthesis of the hepaticocholedoch

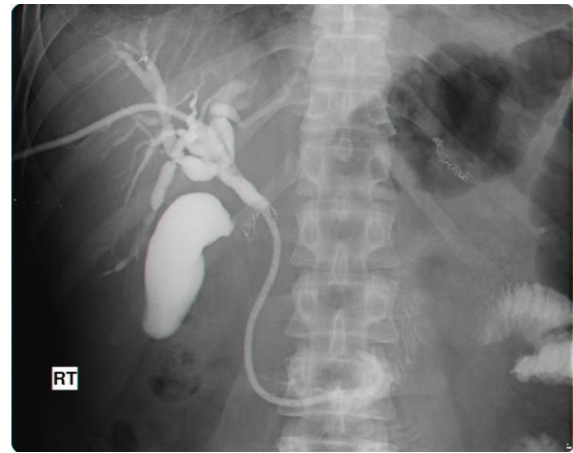


Figure 4. External-internal drainage of the biliary ducts.

The performed radical operative interventions included resection of hepaticocholedoch together with tumor and application of hepaticojejunostomy in 19(61.2%) patients, resection of hepaticocholedoch with tumor, liver resection, application of hepaticojejunostomy in 12(38.7%) patients.

The term of relatively radical operation presents performance of resection surgeries at IVA and IVB stages of disease when the radical procedure is impossible due to stage of disease or due to impossibility of complete tumor resection because of its anatomic localization and growth character, for example IV type (by Bismuth) for lesion of the common hepatic duct bifurcation when tumorous invasion extends highly to segmental ducts. Radicalism in such situation may be achieved only by performing liver transplantation.

Analysis of complications after all operative interventions revealed that hepatic insufficiency was observed in 17,9% of cases, insufficiency of bile digestive anastomosis (BDA) – in 4,48%, gastro-intestinal hemorrhages from acute ulcers connected with operative stress as well as marked shifts in the system of hemocoagulation (reduction of prothrombine time, prothrombine index, increase in fibrinolytic activity, thrombocytopenia) – in 4,48%, intra-abdominal hemorrhages – in 5,76% and cholangitis – in 28,8%. Intra-abdominal hemorrhages and cholangitis occurred more frequently after TTCS and endoprosthesis. In the structure of lethality the association of peritonitis with recurrent gastrointestinal hemorrhages and purulent abscess forming cholangitis with development of biliary sepsis and hepatic-renal insufficiency were of the most importance. After all radical, relatively-radical and palliative interventions 23 patients (14,7%) dead (Table 3).

We studied long-term results of surgical treatment of TPBD. The recurrences of disease were noted at follow-up period from 5 months to 5 years. After operation having relatively-radical character, recurrence occurred in the period from 5 months to 12 months after radical operations – from one year to 5 years. Survival was calculated with method of multiplicand evaluations of Kaplan-Meier. Survival after radical surgeries was achieved 1 years in 94% of patients, 2 years – 82%, 3 years – 45%, 4 years – 15% and 5 years – 12%. Survival after palliative external drainage accounted for 3.2 ± 1.8 months, after internal drainage – 7.0 ± 3.4 months.

We believe that resection of the hepatic ducts in TPBD has radical character only at II stage of tumors with localization of type I by Bismuth-Corlett and only in some cases for type II. For other localizations and stages of cancer of TRBD this intervention has relatively-radical or palliative character.

Table 1. The characteristic of palliative operative interventions

Types of interventions	Quantity of patients	%
Tumor recanalization with external drainage of the bile ducts	61	48,8
BDA	17	13,6
TTCS	33	26,4
Endoprosthesis	14	11,2
Total	125	100

BDA= bile digestive anastomosis; TTCS = transcutaneous transhepatic cholangiostomy

Table 2. Character of the radical operative interventions

Types of interventions	Quantity of patients	%
Resection of hepaticocholedoch together with tumor and application of hepatojejunostomy	19	61.2
Resection of hepaticocholedoch together with tumor, liver resection and application of hepaticojejunostomy	12	38.7
Total	31	100

Table 3. Frequency rate of complications after operative intervention (abs/%).

Variant of surgery	Quantity	Acute hepatic insufficiency	Insufficiency of BDA	Gastrointestinal hemorrhage	Intra-abdomen hemorrhage	Cholangitis	Lethality
Radical	31	4 (12,9)	5 (16,1)	1 (3,2)	2 (6,45)	4 (12,9)	4 (12,9)
Recanalization and external drainage	61	12 (19,6)	-	3 (4,9)	5 (8,1)	23 (37,7)	10 (16,3)
Palliative resection of hepatic ducts with formation of anastomosis	17	4 (23,5)	2 (11,7)	3 (17,6)	-	1 (5,8)	2 (11,7)
Transcutaneous transhepatic cholangiostomy	33	7 (21,2)	-	-	2 (6,1)	9 (27,2)	5 (15,1)
Endoprosthesis	14	1 (7,14)	-	-	-	8 (57,1)	2 (14,2)
Total	156	28 (17,9)	7 (4,48)	7 (4,48)	9 (5,76)	45 (28,8)	23 (14,7)

BDA= bile digestive anastomosis

Diagnosis of these tumors is difficult, since in the first period the disease is asymptomatic. Affecting the proximal bile ducts, the tumor leads to their obturation. The greatest diagnostic value is computed tomography, ultrasound, angiography of the hepatic vessels, retrograde pancreaticholangiography, percutaneous transhepatic cholangiography [12].

Biochemical investigations reveal disorders characteristic of mechanical jaundice and cholestasis. The level of bilirubin and the activity of alkaline phosphatase can be very high. Almost 100% of tumors of the proximal bile ducts show severe changes in the blood coagulation system. The level of tumor markers is increased: carcinoembryonic antigen (CEA) (44-46%), carbohydrate antigen CA19-9 (47-70%), alpha-fetoprotein (19%) [13]. Currently, one of the most informative methods is magnetic resonance imaging (MRI), which allows a clear visualization of tumor, ductal system of the liver and vascular structures.

Ultrasound diagnosis (ultrasound) is one of the most informative methods. Already in the conditions of the clinic, a qualified doctor can determine the syndrome of biliary hypertension with the presence of a block at the level of the gates of the liver [14]. Ultrasound reveals the dilatation of the intrahepatic bile ducts of one or both lobes of the liver and the level of the block without the expansion of the common bile duct below the level of obstruction and without an increase in the gallbladder.

The most clinically important diagnostic method for proximal bile duct cancer identification is the direct contrast of the biliary ducts. Percutaneous transhepatic cholangiography is highly informative in determining the proximal level of biliary tract obstruction and the prevalence of the tumor along the bile ducts. The sensitivity of transhepatic cholangiostomy reaches 95.2%, specificity, according to different data - 85-88%, correctness in the evaluation of resequence - 58%. From the literature review one can observe that there is still no generally accepted diagnostic algorithm for peripheral bile cancer. However, most authors believe that ultrasound, CT or MRI, transhepatic cholangiostomy are of greatest importance for the choice of treatment tactics; Cholangioscopy, angiography, biopsy, laparoscopy are used according to strict indications

CONCLUSION

The optimal complex of differential-diagnostic methods of investigation together with general methods of examination should include the following techniques in the special order: USI of the organs of abdominal cavity, duplex scanning of the portal fissure vessels, CT(SCT) of the abdominal cavity organs, MRI with regimen of cholangiography, ERPCG and TTCG.

At I and II types of tumor by Bismuth-Corlette at the I-II stages of the cancer of proximal bile ducts it would be rationally to perform radical surgical treatment with preliminary decompression of the intrahepatic bile ducts at marked mechanical jaundice that allows reduction of the operation risk and quantity of complications in the patients with severe stage of jaundice.

At diagnosis of clearly nonresectable TPBD and presence of contraindications for surgery the decompression of bile ducts with use of TTCS and, if possible, with use of external-internal drainage or endoprosthesis appeared to be method of choice.

Acknowledgements

This work was supported by Republican Specialized Surgery Center, Tashkent, Republic of Uzbekistan.

Authors' Contributions

All authors contributed equally to this work.

Competing interests

The authors declare that they have no competing interests.

REFERENCES

1. Galperin EI, Kusovlev NF and Chevokin AYu. 1994. Surgical treatment of tumorous obstruction of hepatic ducts in the area of their confluence. Focal liver lesions and hilus tumors of hepatic ducts. *Materials of Second Conf. Surg Hepatol. Kirov*, 166-167.
2. Danilov MB, Glabay VP, Kustov AE, et al. 1997. Surgical treatment of the patients with mechanical jaundice of tumorous etiology. *Ann. Surg Hepatol*, 2: 110-116.
3. Sedov AP. 2003. The cancer of proximal segments of the hepatic duct (Klatskin's tumor): Monography.-Belgorod: *Publ. House BelSU*. Pp.112.
4. Fedorov VD, Vishnevskiy VA, Kubishkin VA et al. 2000. Surgical treatment of the common hepatic duct cancer. *Kremlin med. – M*, 2: 13-16.
5. Aitemeier WA, Gall EA, Zinnenger MM, Hoxworth PL. 1957. *Arch. Surg.*, 75: 450.
6. Ogura Y, Miwamoto R, Tcihata M. et al. 1993. *World J. Surg.*, 17: 85-93.
7. Klatskin G. 1965. Adenocarcinoma of the hepatic duct at its bifurcation within the porta hepatis. An unusual tumor with distinctive clinical and pathological features". *Am. J. Med.*, 38(2): 241–56. PMID 14256720. doi:10.1016/0002-9343(65)90178-6.
8. Karmazanovskiy GG, Fedorov VD, Shipuleva IV. 2000. Spiral computed tomography in the surgical hepatology.
9. Bismuth H, Corlette MB. 1975. *Surg. Gynecol. Obstet.* 140: 170
10. Karimov SHI, Akhmedov RM. 1994. Endobiliary interventions into diagnosis and treatment of patients with mechanical jaundice. Tashkent: IPO after Ibn Sina. Pp. 238-239.
11. Sedov A.P. 2003. The cancer of proximal segments of the hepatic duct (Klatskin's tumor): Monography.-Belgorod:Publ.House BelSU. Pp. 112.
12. Nimura Y, Hayakawa N., Kamiya J, Kondo S, Nagino M, Kanai M. 1995. Hilar cholangiocarcinoma surgical anatomy and curative resection. *Hep. Bil. Pancr. Surg.*, 2: 239-248.
13. Uhlmann D. et al. 2006. Management and outcome in patients with Klatskin-mimicking lesions of the biliary tree. *J Gastrointest Surg.*, 10(8): 1144-50.
14. Altemeier WA, Gall EA, Zinnenger MM, Hoxworh Pl. 1957. Sclerosing carcinoma of major intrahepatic bile duct. *Arch. Surg.*, 15: 450-461.